



PATIENT

Pepper Frederickson

SPECIES

Canine

BREED

Chihuahua

SEX

Male Neutered

AGE

17 years

WEIGHT

6.8lbs

INTERPRETED BY

Maggie Machen
Lamy, DVM
DACVIM (Cardiology)

IMAGING PERFORMED BY

Pamela Harrigan, RDCS

HOSPITAL NAME

Wignall Animal Hospital

REFERRING VET

Dr. Thomas

INVOICE

20766

DATE

8/26/21

PRESENTING CLINICAL SIGNS

History: Presented for restless sleep and panting; started furosemide prior to radiographs as precaution. On follow-up, cardiomegaly seen on radiographs, no CHF. d/c furosemide. BP: 127,129, 136mmHg.

ECHOCARDIOGRAM FINDINGS

2D, m-mode, color flow and Doppler imaging is available.

Left ventricle: The LV diameter is normal with adequate myocardial function. LV wall thicknesses are normal.

Left atrium: The left atrium is mildly dilated.

Mitral valve: The mitral valve is diffusely thickened with mild prolapse into the left atrial lumen. Mild eccentric mitral regurgitation with a normal velocity.

Aortic valve/aorta: The aortic valve is normal in morphology and mobility. Normal aortic outflow velocity; laminar flow. No aortic insufficiency.

Right ventricle: Normal right ventricular diameter and morphology indicating no overt evidence of pulmonary arterial hypertension.

Right atrium: Normal RA dimension.

Tricuspid valve: The tricuspid valve appears thickened with septal prolapse and mild tricuspid regurgitation; borderline normal velocity.

Pulmonic valve/pulmonary artery: The pulmonic valve is normal in morphology and mobility. No pulmonic insufficiency. Normal RVOT velocity; laminar flow.

Pericardium/other: No pericardial or pleural effusion noted. No obvious cardiac masses.

Heart rhythm: ECG reveals a sinus rhythm with an average HR of 130bpm.

2-Dimensional Measurements

Ao diam (cm)	1.0
LA diam (cm)	1.5
LA:Ao (Swe)	1.5
IVS thickness (cm)	0.48
LVID diastole (cm)	2.4
PW thickness (cm)	0.53
LVID systole (cm)	1.3
FS (%)	47

Doppler Measurements

PV Vmax (m/s)	0.6
AoV Vmax (m/s)	1.0
MR Vmax (m/s)	5.8
TR Vmax (m/s)	2.8
TR PG (mmHg)	30

INTERPRETATION OF THE FINDINGS

Chronic degenerative valve disease causing mild mitral and tricuspid regurgitation. Lack of significant left atrial enlargement indicates the current risk for complication is low. No concurrent issues such as systolic dysfunction or pulmonary hypertension are noted in this study. Assessment of progression in the future will help predict long term prognosis, which is highly variable at this stage (B1).

No medications are indicated. These findings would suggest restlessness/panting is unlikely to be cardiogenic in origin.

RECOMMENDATIONS

- Given these findings, no cardiac medications are clearly indicated.
- Omega fatty acid supplementation and mild salt restriction may be of some long-term benefit.



PATIENT

Pepper Frederickson

SPECIES

Canine

BREED

Chihuahua

SEX

Male Neutered

AGE

17 years

WEIGHT

6.8lbs

INTERPRETED BY

Maggie Machen
 Lamy, DVM
 DACVIM (Cardiology)

IMAGING PERFORMED BY

Pamela Harrigan, RDCS

HOSPITAL NAME

Wignall Animal Hospital

REFERRING VET

Dr. Thomas

INVOICE

20766

DATE

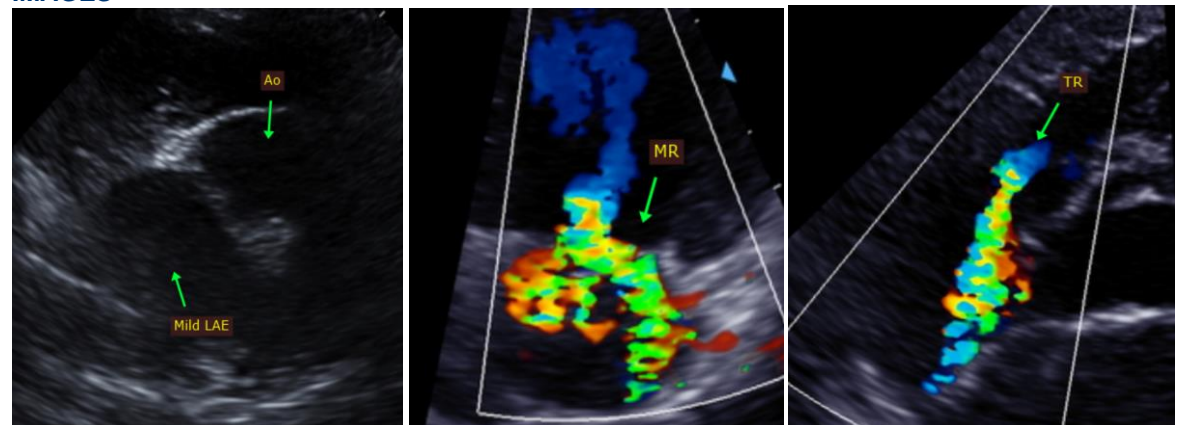
8/26/21

- Anesthetic risk is considered mild if needed. Cardiac protective drug choices (opioid/benzodiazepine premedication, propofol or alfaxalone induction, isoflurane gas) are recommended. Pre-oxygenate for 5-10 minutes prior to induction. Monitor for arrhythmias, hypotension, and hypoxia both intra and post-operatively and intervene as necessary. Mild IV fluid restriction is recommended to avoid fluid overload. Avoid heart rate stimulating drugs such as atropine unless clinically indicated.
- Monitor for development of a cough, labored breathing, exercise intolerance or collapse episodes.

PLAN

- Recommend conservative monitoring with a recheck echocardiogram in 6 months, sooner if any development of clinical signs.

IMAGES



The information and recommendations provided are based on the images presented by the referring veterinarian. No evaluation can be communicated regarding pathology that was not visible in the image/video clips provided.

Thank you for this referral. This report was generated using transcription software, and minor dictation errors may be present. If the clinical or image interpretation does not parallel your findings or if I can be of any further assistance, please contact me.

Maggie Machen Lamy, DVM
 Diplomat of the American College of Veterinary Internal Medicine (Cardiology)
 info@sonopath.com